



HEART ASSOCIATES of NORTHERN CALIFORNIA
 2581 Samaritan Dr. Suite 202
 San Jose, CA 95124
 408-358-3939
 408-358-3797



ECHOCARDIOGRAPHY/DOPPLER REPORT

Name HILLS, BARRY L.
 Age 58
 Birthdate 04/18/1956
 Sex Male

Date 02/17/2015
 Height 190.5 cm
 Weight 136.1 kg
 BP 110/66

Sonographer Ying Wu, RCDS, RVT
 Ref Physician Dr. Dennis I. Penner,
 Diagn.Phys. Felix H. Lee, MD

Referral Reasons:
 IHSS

DIMENSIONS

Ao asc 4.6 cm
 RVIDd 2.5 cm
 IVSd 1.9 cm
 LVIDd 4.8 cm
 LVPWd 1.7 cm
 LVIDs 2.8 cm
 Ao Diam 4.4 cm
 LA Diam 4.0 cm
 LA/Ao 0.90

LAESV Index (A-L) 36.95 ml/m²
 EDV(Teich) 109 ml
 ESV(Teich) 31 ml
 EF(Teich) 72 %
 %FS 41 %
 SV(Teich) 79 ml

DOPPLER

MV E/A Ratio 1.89
 E/E' 13.42
 AV Vmax 1.96 m/s
 AV maxPG 15.35 mmHg
 AV meanPG 10.06 mmHg

FINDINGS:

1. Transthoracic echocardiogram recorded in normal sinus rhythm.
2. LEFT VENTRICLE
 Normal overall left ventricular size and function.
 LVID: 2.8 cm (ES), 4.8 cm (ED); FS: 41 %, EF: 72 %; Basal septal: 1.9 cm, Posterior: 1.7 cm.
 IHSS with normal wall motion.
 LVOT resting : mean gradient of 10 mmHg, peak gradient of 15 mmHg.
 Valsalva: mean gradient of 18 mmHg, peak gradient of 33 mmHg.
3. RIGHT ATRIUM / RIGHT VENTRICLE
 Normal overall right atrial/right ventricular size and function.
4. LEFT ATRIUM
 Moderate LA enlargement LA volume index is 37 ml /m².
5. AORTIC VALVE
 Trileaflet aortic valve sclerosis without aortic stenosis or insufficiency.
6. MITRAL VALVE
 Mitral annular calcification with trace mitral regurgitation. No MVP.
 Mitral inflow velocities are normal.
7. TRICUSPID VALVE
 No tricuspid regurgitation. Right ventricular systolic pressure is normal.
8. PULMONIC VALVE
 Trace pulmonic insufficiency.
9. PERICARDIUM
 No evidence of pericardial effusion.
10. Aorta root is dilated measuring 4.4 cm.
11. Ascending aorta is dilated measuring 4.6 cm.

INTERPRETATION

Comparison to a prior study dated 06/08/12 reveals interval regression of IHSS (1.9cm, LVOT MG 18 mm HG), trace MR, trace PI, ascending aortic aneurysm and preserved LV EF 72% on his current regimen.

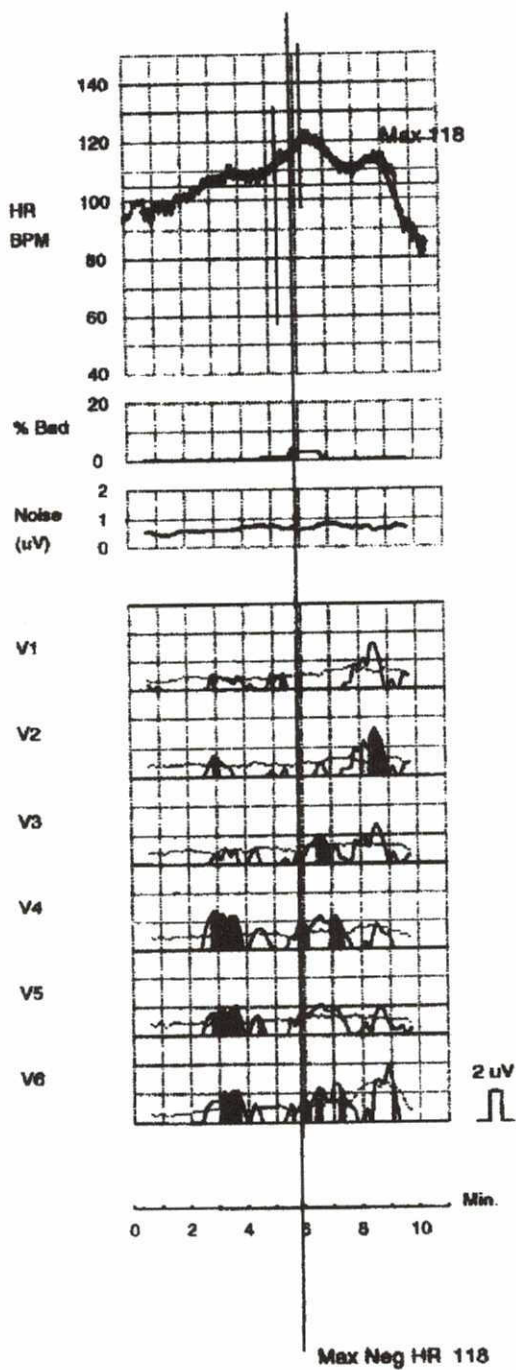
Signed: Felix H. Lee, MD

Date: 2/17/15

ALTERNANS PRECORDIAL TREND SUMMARY

Patient : HILLS, BARRY
 ID : 04-18-56

Date : 8/29/13
 Time : 00:36:47



Preliminary - Physician Must Review

No sustained alternans and Max Neg HR >= 105, consistent with negative tracing.


Cambridge Heart, Inc.
 *01,14 12,0 11,0 10,0

TEST0111 Check Leads: 000000000000
 1.34#US 111 d6.1J.JJi610200 0 00.00.000000000

Heartwave 1.34#US 60 Hz
 *1,14 4,0 3,0 2,0

TRANSTHORACIC ECHO COMPLETE WITH DOPPLER

Collected on Oct 18, 2016 2:13 PM

If you have questions or concerns regarding your test results, contact
the clinician who ordered the test. 

Results

Heart Associates of Northern California
2581 Samaritan Dr. Suite 202
San Jose, CA 95124
Phone (408) 358-3939
Fax (408) 358-3797

Adult Transthoracic Echocardiogram Report

Name: HILLS, BARRY Study Date: 10/18/2016 Height: 75 in
MRN: 61147341 Patient Location: PMSSDIKD Weight: 338 lb
DOB: 04/18/1956 Gender: Male BSA: 2.7 m²
Age: 60 yrs Accession #: PSK16002648479 BP: 132/80 mmHg
Ordering Physician: LEE, FELIX Performed By: Wu, Ying
Referring Physician: Dheeraj Kamra,
Reason For Study: IHSS

Interpretation Summary

Normal LV size / function, LVID 3.1/5.2, IHSS (2.2/1.7), LVOT MG 17 mm Hg > 42 mm Hg, FS:
40%,
EF: 71%
Mild LA enlargement (4.0, 39.7)
Trileaflet AV, Calcified
Mild MAC, Trace MR
Normal TV
Trace PI
Dilated Aortic Root 4.4 cm

Examination Performed: A complete two-dimensional transthoracic echocardiogram with color

flow and spectral Doppler was performed. The heart rhythm was sinus.

Left Ventricle: The left ventricle is normal in size. There is asymmetric septal hypertrophy. Basal septal; 2.2 cm, posterior wall: 1.7 cm. LVOT resting gradient: mean of 17 mmHg, peak of 31 mmHg;

Valsalva gradient: mean of 36-42 mmHg, peak of 70-86 mmHg. Normal regional and global systolic

function. The estimated ejection fraction is 71%.

Right Ventricle: The right ventricle is normal in size with normal systolic function.

Left Atrium: The left atrium is mildly enlarged. The left atrial volume index is 39.7 ml/m².

Right Atrium: The right atrium is normal in size.

Aortic Valve: The leaflets are calcified with normal mobility. The forward flow velocity is normal. There is no aortic regurgitation.

Mitral Valve: There is mild annular calcification. There is trivial mitral regurgitation.

Tricuspid Valve: There is no significant tricuspid regurgitation.

Pulmonic Valve: There is trace pulmonic regurgitation.

Aortic Root: The ascending aorta is mildly dilated. measuring 4.4 cm.

Pericardium: There is no pericardial effusion.

Inferior Vena Cava: The inferior vena cava is normal in size and collapses with inspiration.

MMode/2D Measurements & Calculations

RVDd: 2.9 cm LVIDd: 5.2 cm FS: 40.4 %

IVSd: 2.2 cm LVIDs: 3.1 cm EF(Teich): 70.7 %

IVSs: 2.8 cm LVPWs: 2.3 cm

LVPWd: 1.7 cm

Ao root diam: 4.4 cm LA Vol Index: 39.7 ml/m²

LA dimension: 4.0 cm

Doppler Measurements & Calculations

MV E max vel: 130.0 cm/sec Lat Peak E' Vel: 7.0 cm/sec Med Peak E' Vel: 7.2 cm/sec

MV A max vel: 45.9 cm/sec E/E' lat: 18.5 E/E' med: 18.0

MV E/A: 2.8

MV dec time: 0.24 sec

LV V1 mean: 191.5 cm/sec

LV V1 mean PG: 17.0 mmHg

LVOT VTI: 62.7 cm

Reference Ranges


—
Measurement Normal Mild Moderate Severe 2D / M-Mode
LV EDV Index (ml/m2) 35-75 >75 >86 >96 LVIDd (cm) 3.7-5.7cm
LV ESV Index (ml/m2) 12-30 >30 >36 >42 LVIDs (cm)
EF% >55 45-54 35-44 <35 IVSd (cm) 0.6-1.4cm
LA Volume Index (ml/m2) <34 >35 >42 >48 LVPWd (cm) 0.5-1.3cm
Tricuspid Gradient (mmHg) <30 >35 >45 >55 LA (cm) 2.5-4.4cm
Ao Root (cm) 2.0-4.0cm

—
Reading Physician: Electronically signed by: Felix Lee, MD on 10/21/2016 01:45 AM

Ordering provider: Felix Lee, MD
Reading physician: Felix Lee, MD
Study date: Oct 18, 2016 3:46 PM
Collection date: Oct 18, 2016 2:13 PM
Result date: Oct 21, 2016 1:45 AM
Result status: Final

TRANSTHORACIC ECHO W/ DOPPLER CMPLT

Collected on Jul 10, 2017 9:38 AM

If you have questions or concerns regarding your test results, contact
the clinician who ordered the test. 

Results

Impression

1. The left ventricle size is normal.
2. Overall left ventricular systolic function is normal with, an EF between 60 - 65 %.
3. Severe asymmetric septal hypertrophy with septal thickness 20 - 29 mm.
4. Gradient across the LVOT at rest of 30mmHg and with Valsalva, 62mmHg
5. The left atrium is markedly dilated.
6. The right ventricle is normal in size.
7. The right ventricular systolic function is normal.
8. The right atrium is mildly enlarged.
9. The ascending aorta is dilated measuring up to 4.6cm.

Narrative

Echocardiography Report

Name HILLS, BARRY
Birthdate 04/18/1956
Age 61
Sex Male
Height 190.5 cm
Weight 158.8 kg
BSA 2.78 m²

Date 07/10/2017
Patient Id 11759814
Sonographer Teresa Martina RCS

Diagnosis HX HOcm/ ASCENDING AORTIC ANEURYSM/
Ref.Phys. DR HICKEY/ DAVID ROBERTS/

Electronically signed off by:Orson D. Go M.D. F.A.C.C.

2D Measurements

IVSd 2.4 cm
Ao asc 4.6 cm
RVIDd 2.5 cm
IVC 18.36 mm

Mitral Valve Doppler

MV E Vel 1.23 m/s
MV DecT 242 ms
MV Dec Slope 5.1 m/s²
MV A Vel 0.62 m/s
MV E/A Ratio 1.98
E' Sept 0.08 m/s
E/E' Sept 15.12
E' Lat 0.07 m/s
E/E' Lat 17.97
E' Avg 0.07 m/s
E/E' Avg 16.42

Tricuspid Valve Doppler

TR Vmax 2.72 m/s
TR maxPG 29.69 mmHg
RAP 5.00 mmHg
RVSP 34.69 mmHg

M-Mode Measurements

Ao Diam 4.5 cm
LA Diam 4.3 cm
AV Cusp 1.8 cm
LA/Ao 0.94
IVSd 2.2 cm
LVIDd 5.5 cm
LVPWd 1.5 cm
LVIDs 3.5 cm
EF(Teich) 66 %
%FS 36 %

RVIDd 2.3 cm

Aortic Valve Doppler

Pulmonary Valve Doppler

PV AccT 123 ms

PV Acc Slope 8.6 m/s²

Findings

Study quality: Technically limited study. Due to body habitus.

Left Ventricle: The left ventricle size is normal. Overall left ventricular systolic function is normal with an EF between 60 - 65 %. Severe asymmetric septal hypertrophy with septal thickness 20 - 29 mm. Gradient across the LVOT at rest of 30mmHg and with Valsalva, 62mmHg

Left Atrium: The left atrium is markedly dilated.

Right Ventricle: The right ventricle is normal in size. The right ventricular systolic function is normal.

Right Atrium: The right atrium is mildly enlarged.

Aortic Valve: The aortic valve is trileaflet and appears structurally normal. There is mild aortic valve sclerosis without stenosis. There is no evidence of aortic regurgitation.

Mitral Valve: The mitral valve was not well visualized. Mild mitral regurgitation is present.

Tricuspid Valve: The tricuspid valve appears structurally normal. Trace tricuspid regurgitation present. There is no evidence of pulmonary hypertension.

Pulmonic Valve: Trace/mild (physiologic) pulmonic regurgitation.

Pericardium: There is no pericardial effusion.

Aorta: The ascending aorta is dilated measuring up to 4.6cm. Aortic root is not well seen

IVC/Hepatic Veins: The inferior vena cava is normal.

Conclusions

1. The left ventricle size is normal.
2. Overall left ventricular systolic function is normal with, an EF between 60 - 65 %.
3. Severe asymmetric septal hypertrophy with septal thickness 20 - 29 mm.
4. Gradient across the LVOT at rest of 30mmHg and with Valsalva, 62mmHg
5. The left atrium is markedly dilated.
6. The right ventricle is normal in size.
7. The right ventricular systolic function is normal.
8. The right atrium is mildly enlarged.
9. The ascending aorta is dilated measuring up to 4.6cm.

Diagn.Phys. signoff Electronically signed off by:Orson D. Go M.D. F.A.C.C.
Signoff date 2017/07/26 06:47

EJECTION FRACTION

%

Value
60-65

Authorizing provider: Orson Go, MD
Collection date: Jul 10, 2017 9:38 AM
Result date: Jul 26, 2017 9:38 AM
Result status: Final

TRANSTHORACIC ECHO COMPLETE WITH DOPPLER

Collected on Nov 26, 2018 12:00 AM

If you have questions or concerns regarding your test results, contact
the clinician who ordered the test. ✓

Results

Sutter Medical Foundation
, CA

Transthoracic Echocardiogram

Name: HILLS, BARRY L

MR #: 61147341

DOB: 04/18/1956

Age: 62 years

Gender: Male

Study date: 11/26/2018

Accession #: BBK18000764207

Account #: 908453105

Height: 75 in

Weight: 349.4 lb

BSA: 2.78 m squared

Location: Sacramento, Sutter Cardiac Imaging: IAC - Accredited

Indications: Hypertrophic Obstructive Cardiomyopathy.
Idiopathic Hypertrophic Sub-aortic Stenosis. Paroxysmal
Supraventricular Tachycardia. Thoracic Aortic Aneurysm.

Reading Physician: Richard P. Ericson, M.D.

Ordering Physician: David K. Roberts, M.D.

Cardiac Sonographer: Collin McClain, RDCS

Primary Care Physician: DYLAN B. HICKEY

HISTORY: PRIOR HISTORY: Hypertrophic Obstructive Cardiomyopathy.
Idiopathic Hypertrophic Sub-aortic Stenosis. Paroxysmal
Supraventricular Tachycardia. Thoracic Aortic Aneurysm.
Hypertension. Hyperlipidemia.

PROCEDURE: This was a routine study. The transthoracic approach

was used. The study included complete 2D imaging, M-mode, complete spectral Doppler, and color Doppler. The heart rate was 51 bpm, at the start of the study. BP taken sitting. The patient's rhythm was sinus bradycardia. Blood pressure was 122/66. Image quality was adequate.

LEFT VENTRICLE: Size was normal. Systolic function was normal. Ejection fraction was estimated to be 60 %. There were no regional wall motion abnormalities. There was moderate assymetrical hypertrophy of the septum. **DOPPLER:** Doppler parameters were consistent with restrictive physiology, indicative of decreased left ventricular diastolic compliance and/or increased left atrial pressure. Left atrial pressure was elevated.

RIGHT VENTRICLE: The size was normal. Systolic function was normal. Wall thickness was normal.

LEFT ATRIUM: The atrium was severely dilated.

RIGHT ATRIUM: Size was normal.

MITRAL VALVE: There was moderate calcification. There was normal leaflet separation. **DOPPLER:** There was no evidence for stenosis. There was no significant regurgitation.

AORTIC VALVE: The valve was trileaflet. Leaflets exhibited moderate calcification and good mobility. **DOPPLER:** There was mild stenosis. There was no significant regurgitation.

TRICUSPID VALVE: The valve structure was normal. There was normal leaflet separation. **DOPPLER:** The transtricuspid velocity was within the normal range. There was no evidence for stenosis. There was trace regurgitation.

PULMONIC VALVE: Leaflets exhibited normal thickness, no calcification, and normal cuspal separation. **DOPPLER:** The transpulmonic velocity was within the normal range. There was no regurgitation.

AORTA: The root exhibited dilatation measuring 4.8 cm There was dilatation of the ascending aorta measuring 4.8 cm.

PULMONARY ARTERY: **DOPPLER:** Systolic pressure was mildly increased. Estimated peak pressure was 36 mmHg. Assuming right

atrial pressure of 10 mmHg.

PERICARDIUM: There was no pericardial effusion. The pericardium was normal in appearance.

SYSTEM MEASUREMENT TABLES

2D

Ao Arch Diam: 3.73 cm

Asc Ao: 4.7 cm

LVOT Diam: 2.36 cm

LA Diam: 5.09 cm

LAESV Index (A-L): 75.28 ml/m²

LAESV(A-L): 210.02 ml

%FS: 33.93 %

IVSd: 1.79 cm

LVIDd: 4.49 cm

LVIDs: 2.97 cm

LVPWd: 1.31 cm

IVC: 1.89 cm

RAAs: 24.88 cm²

RAESV MOD: 77.08 ml

RVIDd: 3.92 cm

CW

AV Vmax: 2.56 m/s

AV Vmean: 1.88 m/s

AV maxPG: 26.16 mmHg

AV meanPG: 15.78 mmHg

PRend Vmax: 0.64 m/s

PV Vmax: 0.86 m/s

PV maxPG: 2.98 mmHg

TR Vmax: 2.56 m/s

TR maxPG: 26.28 mmHg

MM

TAPSE): 2.04 cm

PW

AVA (VTI): 3.45 cm²

AVA Vmax: 2.91 cm²

LVOT Vmax: 1.7 m/s

E': 0.07 m/s

E/E': 18.66

MV A Vel: 0.59 m/s

MV Dec Slope: 5.74 m/s²

MV DecT: 237.58 ms

MV E Vel: 1.36 m/s

MV E/A Ratio: 2.32

TV S: 0.14 m/s

SUMMARY:

- Left ventricle:

- Systolic function was normal. Ejection fraction was estimated to be 60 %.

- There were no regional wall motion abnormalities.

- There was moderate assymetrical hypertrophy of the septum.

- Doppler parameters were consistent with restrictive physiology, indicative of decreased left ventricular diastolic compliance and/or increased left atrial pressure.

- Left atrium:

- The atrium was severely dilated.

- Mitral valve:

- There was moderate calcification.

- Aortic valve:

- The valve was trileaflet. Leaflets exhibited moderate calcification and good mobility.

- There was mild stenosis.

- Aorta:

- There was dilatation of the ascending aorta measuring 4.8 cm.

- Pulmonary arteries:

- Systolic pressure was mildly increased. Estimated peak pressure was 36 mmHg. Assuming right atrial pressure of 10 mmHg.

Prepared and signed by

Richard P. Ericson, M.D.

Signed 11/27/2018 07:38:37

Authorizing provider: David Roberts, MD

Reading physician: Richard Ericson, MD

Study date: Nov 26, 2018 10:30 AM

Collection date: Nov 26, 2018 12:00 AM


Result date: Nov 27, 2018 7:38 AM

Result status: Final

MyChart® licensed from Epic Systems Corporation© 1999 - 2025

TRANSTHORACIC ECHO W/ DOPPLER CMPLT

Collected on Feb 06, 2020 8:15 AM

If you have questions or concerns regarding your test results, contact the clinician who ordered the test. 

Results

Impression

Conclusions

1. The left ventricle size is normal.
2. Overall left ventricular systolic function is normal with, an EF between 60 - 65 %. LVOT gradient at rest 54mmHg with valsalva 74mmHg
3. Severe asymmetric septal hypertrophy with septal thickness 20 - 29 mm.
4. Evidence of dynamic ventricular outflow tract obstruction; maximum gradient across the LVOT is 54mmHg.
5. The left atrium is moderately dilated.
6. The right ventricle is mildly enlarged measuring between 3.4 - 3.7 cm.
7. The right ventricular systolic function is normal.
8. Mild mitral annular calcification present.
9. Mild regurgitation is present.
10. The aortic root and ascending aorta are dilated measuring up to 4.8cm

Diagn.Phys. signoff Electronically signed off by: Orson D. Go M.D. F.A.C.C.
Signoff date 02/06/2020 14:46

Narrative

Echocardiography Report

Name HILLS, BARRY
Birthdate 04/18/1956

Age 63 years
Sex Male
Height 190.5 cm
Weight 174.2 kg
BSA 2.90 m²

Date 02/06/2020
Patient Id 61147341
Sonographer Patricia Boals RCS
Diagnosis HOCM/HTN
Ref.Phys. D.HICKEY

Electronically signed off by: Orson D. Go M.D. F.A.C.C.

2D Measurements

LVOT Diam 2.9 cm
Ao asc 4.3 cm
RVIDd 3.4 cm
IVC 20.73 mm

Mitral Valve Doppler

MV PHT 84 ms
MVA By PHT 2.6 cm²
MV Vmax 1.82 m/s
MV Vmean 0.70 m/s
MV maxPG 13.22 mmHg
MV meanPG 3.08 mmHg
MV VTI 56.4 cm
MVA (VTI) 4.7 cm²

Tricuspid Valve Doppler

TR Vmax 2.74 m/s
TR maxPG 29.94 mmHg
RAP 5.00 mmHg
RVSP 34.94 mmHg

M-Mode Measurements

IVSd 1.2 cm
LVIDd 5.4 cm
LVPWd 0.7 cm
LVIDs 3.5 cm

LVPWs 1.3 cm
EDV(Teich) 139 ml
ESV(Teich) 52 ml
EF(Teich) 62 %
%FS 34 %
SV(Teich) 87 ml
Ao Diam 4.8 cm
LA Diam 4.2 cm
AV Cusp 2.0 cm
LA/Ao 0.86

Aortic Valve Doppler

LVOT Vmax 0.01 m/s
LVOT maxPG 0.00 mmHg
LVOT Vmax 1.54 m/s
AVA Vmax, Pt 0.0 cm²

Pulmonary Valve Doppler

PV Vmax 1.01 m/s
PV maxPG 4.06 mmHg
PV AccT 101 ms
PV Acc Slope 6.7 m/s²

Findings

ECG rhythm: Atrial fibrillation.

Study quality: Technically difficult study due to body habitus.

Left Ventricle: The left ventricle size is normal. Overall left ventricular systolic function is normal with, an EF between 60 - 65 %. LVOT gradient at rest 54mmHg with valsalva 74mmHg. Severe asymmetric septal hypertrophy with septal thickness 20 - 29 mm. Evidence of dynamic ventricular outflow tract obstruction; maximum gradient across the LVOT is 71mmHg.

Left Atrium: The left atrium is moderately dilated.

Right Ventricle: The right ventricle is mildly enlarged measuring between 3.4 - 3.7 cm. The right ventricular systolic function is normal.

Right Atrium: The right atrial size is normal.

Aortic Valve: The aortic valve was not well visualized. There is no evidence of aortic

regurgitation. There is no evidence of aortic stenosis.

Mitral Valve:Mild mitral regurgitation is present. Mild mitral annular calcification present.

Tricuspid Valve:The tricuspid valve appears structurally normal. Mild tricuspid regurgitation present. There is no evidence of pulmonary hypertension.

Pulmonic Valve:Mild regurgitation is present.

Pericardium:There is no pericardial effusion.

Aorta:The aortic root and ascending aorta are dilated measuring up to 4.8cm

IVC/Hepatic Veins:The inferior vena cava is normal.

Septum:IVS measures 2.4cm

Conclusions

1. The left ventricle size is normal.
2. Overall left ventricular systolic function is normal with, an EF between 60 - 65 %. LVOT gradient at rest 54mmHg with valsalva 74mmHg
3. Severe asymmetric septal hypertrophy with septal thickness 20 - 29 mm.
4. Evidence of dynamic ventricular outflow tract obstruction; maximum gradient across the LVOT is 54mmHg.
5. The left atrium is moderately dilated.
6. The right ventricle is mildly enlarged measuring between 3.4 - 3.7 cm.
7. The right ventricular systolic function is normal.
8. Mild mitral annular calcification present.
9. Mild regurgitation is present.
10. The aortic root and ascending aorta are dilated measuring up to 4.8cm

Diagn.Phys. signoff Electronically signed off by: Orson D. Go M.D. F.A.C.C.

Signoff date 02/06/2020 14:46

EJECTION FRACTION

%

Value

60-65%

Authorizing provider: Orson Go, MD


Collection date: Feb 06, 2020 8:15 AM

Result date: Feb 07, 2020 9:35 AM

Result status: Final

TRANSTHORACIC ECHO COMPLETE WITH DOPPLER

Collected on Mar 19, 2021 12:00 AM

If you have questions or concerns regarding your test results, contact
the clinician who ordered the test. 

Results

Sutter Roseville Medical Center
One Medical Plaza
Roseville, CA 95661
(916)781-1277

Transthoracic Echocardiogram

Name: HILLS, BARRY L
MR #: 61147341
DOB: 04/18/1956
Age: 64 years
Gender: M
Study date: 03/19/2021
Accession #: RVK21000728321
Account #: 1088332746
Height: 75 in
Weight: 399.1 lb
BSA: 2.95 m²_{3/4}
Location: Inpatient

Indications: CHF.

Reading Physician: Rishi Menon, M.D.
Ordering Physician: NASR, NAVA
Cardiac Sonographer: Jesslyn Fagundes

PROCEDURE: This was a routine study. The transthoracic approach was used. The study included complete 2D imaging, M-mode, complete spectral Doppler, and color Doppler. Echocardiographic views were limited due to obesity. This was a technically difficult study.

LEFT VENTRICLE: Size was normal. Systolic function was

hyperdynamic. Ejection fraction was estimated in the range of 65 % to 75 %. There were no regional wall motion abnormalities. There was moderate assymetrical hypertrophy of the septum. DOPPLER: There was dynamic obstruction in the outflow tract, with a peak gradient of 84 mmHg. There was dynamic obstruction during Valsalva in the outflow tract, with a peak gradient of 166 mmHg. Left ventricular diastolic function parameters were normal.

VENTRICULAR SEPTUM: Thickness was markedly increased.

RIGHT VENTRICLE: The size was normal. Systolic function was normal.

LEFT ATRIUM: The atrium was mildly to moderately dilated.

ATRIAL SEPTUM: No defect or patent foramen ovale was identified by color Doppler.

RIGHT ATRIUM: Size was normal.

MITRAL VALVE: There was moderate calcification. There was normal leaflet separation. There was mild systolic anterior motion.

DOPPLER: The transmitral velocity was within the normal range. There was no evidence for stenosis. There was mild regurgitation.

AORTIC VALVE: There was anterior (immediately subvalvar) left ventricular outflow obstruction. The valve was trileaflet. Leaflets exhibited normal thickness, mild calcification, and normal cuspal separation. DOPPLER: There was no regurgitation.

TRICUSPID VALVE: The valve structure was normal. There was normal leaflet separation. DOPPLER: There was no evidence for stenosis. There was mild regurgitation.

PULMONIC VALVE: Leaflets exhibited normal thickness, no calcification, and normal cuspal separation. DOPPLER: There was trace regurgitation.

AORTA: The root exhibited mild dilatation.

SYSTEMIC VEINS: IVC: The inferior vena cava was dilated. Inspiratory collapse was less than 50%.

PULMONARY ARTERY: DOPPLER: Unable to quantify systolic pressure.

PERICARDIUM: There was no pericardial effusion. The pericardium was normal in appearance.

SYSTEM MEASUREMENT TABLES

2D

IVSd: 2.05629 cm

LVIDd: 5.55938 cm

LVIDs: 3.82632 cm

LVOT Diam: 2.06978 cm

LVPWd: 1.45472 cm

SUMMARY:

- Left ventricle:

- Systolic function was hyperdynamic. Ejection fraction was estimated in the range of 65 % to 75 %.

- There were no regional wall motion abnormalities.

- There was moderate assymetrical hypertrophy of the septum.

- There was dynamic obstruction during Valsalva in the outflow tract, with a peak gradient of 166 mmHg.

- Ventricular septum:

- Thickness was markedly increased.

- Left atrium:

- The atrium was mildly to moderately dilated.

- Mitral valve:

- There was moderate calcification.

- There was mild systolic anterior motion.

- There was mild regurgitation.

- Aortic valve:

- The valve was trileaflet. Leaflets exhibited normal thickness, mild calcification, and normal cuspal separation.

- Aorta:

- The root exhibited mild dilatation.

- IVC, hepatic veins:

- The inferior vena cava was dilated.

- Inspiratory collapse was less than 50%.

Prepared and signed by

Rishi Menon, M.D.

Signed 03/19/2021 20:25:01

Ordering provider: Nava Nasr, MD

Reading physician: Rishi Menon, MD

Study date: Mar 19, 2021 10:15 AM


Collection date: Mar 19, 2021 12:00 AM

Result date: Mar 19, 2021 8:25 PM

Result status: Final

TRANSTHORACIC ECHO W/ DOPPLER CMPLT

Collected on Oct 04, 2022 10:43 AM

If you have questions or concerns regarding your test results, contact
the clinician who ordered the test. 

Results

Impression

CONCLUSIONS:

1. Normal left ventricular size. Normal left ventricular size. Severe left ventricular hypertrophy. With valsalva, the outflow gradient is 48.20 mmHg. LV Ejection Fraction, visually, is 55-60 %.
2. Normal right ventricular size. Normal right ventricular size.
3. Mitral valve leaflets appear mildly thickened. Mild mitral annular calcification.
4. The aortic cusps appear mildly thickened. Aortic cusps appear mildly calcified.
5. The ascending aorta is 4.8 cm.

Narrative

Transthoracic Echocardiographic Report

Patient Name: HILLS, BARRY Patient ID: 61147341

DOB: 04-18-1956 (66y 5m) Study Date: 10/04/2022 8:11:38 AM

Gender: M Accession #: RCMA

Sonographer: Saheba Siddiqui RCDS Ref Provider:

Height(Inch): 73 BSA: 3.02

Weight(Lb): 389.99 Heart Rate: 48

BMI: 51.45 Quality: Technically difficult study due to patient body habitus.

-

PROCEDURES:

Echocardiographic Report: Transthoracic complete echo, 2D, spectral and tissue Doppler, color flow Doppler, M-mode.

INDICATIONS:

HOCM, HTN, PSVT, SOB.

CONCLUSIONS:

1. Normal left ventricular size. Normal left ventricular size. Severe left ventricular hypertrophy. With valsalva, the outflow gradient is 48.20 mmHg. LV Ejection Fraction, visually, is 55-60 %.
2. Normal right ventricular size. Normal right ventricular size.
3. Mitral valve leaflets appear mildly thickened. Mild mitral annular calcification.
4. The aortic cusps appear mildly thickened. Aortic cusps appear mildly calcified.
5. The ascending aorta is 4.8 cm.

FINDINGS:

Left Ventricle: Normal left ventricular size. Normal left ventricular size. Severe left ventricular hypertrophy. With valsalva, the outflow gradient is 48.20 mmHg. LV Ejection Fraction, visually, is 55-60 %.

Right Ventricle: Normal right ventricular size. Normal right ventricular size.

Left Atrium: Normal left atrial size.

Right Atrium: Normal right atrial size.

Atrial Septum: The interatrial septum is normal in appearance.

Mitral Valve: Mitral valve leaflets appear mildly thickened. There is trivial mitral regurgitation. Mild mitral annular calcification. The mitral valve area by pressure half-time is 1.6 cm². The mitral valve area by continuity equation (using MVA VTI) is 3.7 cm². The peak transmitral gradient is 6.99 mmHg. The mean transmitral gradient is 2.28 mmHg.

Aortic Valve: The aortic cusps appear mildly thickened. Aortic cusps appear mildly calcified. No aortic regurgitation seen. The peak transaortic gradient is 34.34 mmHg. The mean transaortic gradient is 16.26 mmHg. The peak velocity across the aortic valve is 2.93 m/s.

Tricuspid Valve: The tricuspid valve is not well visualized. There is trace tricuspid regurgitation. The estimated right ventricular systolic pressure is 20 mmHg.

Pulmonic Valve: The pulmonic valve is not well visualized.

Pericardium: Normal pericardium without evidence of pericardial effusion.

Aorta: There is mild aortic root dilation. The ascending aorta is 4.8 cm.

IVC: IVC not visualized.

MEASUREMENTS:

2D/MM Value Range Doppler Value

LVIDd 2D 5.48 cm [4.20 - 5.80] AV Peak Vel 2.93 m/s

LVIDs 2D 3.55 cm [2.50 - 4.00] AV Peak PG 34.34 mmHg

IVSd 2D 2.03 cm [0.60 - 1.00] AV Mean PG 16.26 mmHg

LVPWd 2D 1.58 cm [0.60 - 1.00] AV VTI 78.15 cm

LV FS 2D 35.18 % [25.00 - 43.00] LVOT Peak Vel 3.54 m/s

LV Mass 2D 493.85 g LVOT Peak PG 50.14 mmHg

LV Mass Index 2D 163.53 LVOT Mean PG 20.13 mmHg

RWT 0.58 LVOT VTI 74.33 cm

EDV 2D 146.19 LVOT Diam 1.92 cm
ESV 2D 52.63 AVA VTI 2.75 cm²
EF Teich 2D 64 % AVA Vmax 3.50 cm²
LA Dimension 2D 3.32 cm [3.00 - 4.00] LVOT/AV VTI 0.95 - Dimensionless index (DVI)
LA Dimension MM 3.56 cm [3.00 - 4.00] MV E Peak Vel 1.58 m/s
LA Volume BP 47.98 ml MV A Peak Vel 0.61 m/s
LA Volume Index 15.89 MV E/A 2.58 ratio
RVDd 2D 3.17 cm [2.00 - 3.00] MV Peak Vel 1.32 m/s
AoR Diam MM 4.07 cm [3.10 - 3.70] MV Peak PG 6.99 mmHg
ACS MM 2.24 cm MV Mean PG 2.28 mmHg
Asc Ao Diam 2D 4.80 cm [2.60 - 3.40] MV VTI 57.44 cm
MV PHT 139.67 msec
MVA PHT 1.58 cm²
MV Decel Time 258.49 msec
TR Peak Vel 1.92 m/s
TR Peak PG 14.7 mmHg
RA Pressure 5.00 mmHg
RVSP 19.70
PV Peak Vel 1.14 m/s
PV Peak PG 5.17 mmHg
PV Accel Time 110.73 msec
MVA VTI 3.73 cm

Electronically Signed By:
Orson Go, MD
2022-10-17 09:13:48 PDT

EJECTION FRACTION


%

Value
55-60

Authorizing provider: Orson Go, MD
Collection date: Oct 04, 2022 10:43 AM
Result date: Oct 04, 2022 10:43 AM
Result status: Final

TRANSTHORACIC ECHO W/ DOPPLER CMPLT

Collected on Jul 25, 2025 4:14 PM

If you have questions or concerns regarding your test results, contact the clinician who ordered the test. 

Results

Impression

CONCLUSIONS:

1. Normal left ventricular size and systolic function. With valsalva, the outflow gradient is 80.88mmHg. LV Ejection Fraction, visually, is 55-60 %. There is asymmetric septal hypertrophy.
2. Moderately dilated right ventricle. Normal right ventricular systolic function.
3. LA is dilated.
4. Mildly dilated right atrium.
5. Mitral valve is not well visualized. There is mild mitral valve regurgitation. The mean transmitral gradient is 4.68 mmHg.
6. Trileaflet aortic valve. Trace aortic valve regurgitation. The mean transaortic gradient is 14.07 mmHg.
7. There is mild tricuspid regurgitation. The estimated right ventricular systolic pressure is 46 mmHg.
8. There is severe aortic root dilation. There is moderate ascending aorta dilation. The aortic root diameter 2D is 4.85 cm. The ascending aorta is 4.74 cm.
9. The IVC (inferior vena cava) was >2.1 cm and collapsibility >50%. The RA pressure is estimated to be 8 mmHg.

Narrative

Transthoracic Echocardiographic Report

Patient Name: HILLS, BARRY Patient ID: 61147341

DOB: 04-18-1956 (69y 3m) Study Date: 07/25/2025 4:14:02 PM

Gender: M Accession #: RCMA

Sonographer: Lindsey Steinmetz, RCS Ref Provider:

Height(Inch): 72 BSA: 2.89

Weight(Lb): 363 Heart Rate: 68

BMI: 49.23 Quality: Technically difficult study due to patient body habitus.

-

PROCEDURES:

Echocardiographic Report: Transthoracic complete echo, 2D, spectral and tissue Doppler, color flow Doppler, M-mode.

INDICATIONS:

I71.9 Aortic aneurysm of unspecified site, without rupture, I48.91 Unspecified atrial fibrillation, and HOCM.

CONCLUSIONS:

1. Normal left ventricular size and systolic function. With valsalva, the outflow gradient is 80.88mmHg. LV Ejection Fraction, visually, is 55-60 %. There is asymmetric septal hypertrophy.
2. Moderately dilated right ventricle. Normal right ventricular systolic function.
3. LA is dilated.
4. Mildly dilated right atrium.
5. Mitral valve is not well visualized. There is mild mitral valve regurgitation. The mean transmitral gradient is 4.68 mmHg.
6. Trileaflet aortic valve. Trace aortic valve regurgitation. The mean transaortic gradient is 14.07 mmHg.
7. There is mild tricuspid regurgitation. The estimated right ventricular systolic pressure is 46 mmHg.
8. There is severe aortic root dilation. There is moderate ascending aorta dilation. The aortic root diameter 2D is 4.85 cm. The ascending aorta is 4.74 cm.
9. The IVC (inferior vena cava) was >2.1 cm and collapsibility >50%. The RA pressure is estimated to be 8 mmHg.

FINDINGS:

Left Ventricle: Normal left ventricular size and systolic function. With valsalva, the outflow gradient is 80.88mmHg. LV Ejection Fraction, Teichholz 2D, is 53 %. LV Ejection Fraction, visually, is 55-60 %. There is asymmetric septal hypertrophy.

Right Ventricle: Moderately dilated right ventricle. Normal right ventricular systolic function.

Left Atrium: LA is dilated.

Right Atrium: Mildly dilated right atrium.

Atrial Septum: No shunt by color Doppler.

Mitral Valve: Mitral valve is not well visualized. There is mild mitral valve regurgitation. Moderate mitral annular calcification. The mitral valve area by pressure half-time is 2.8 cm². The mitral valve area by continuity equation (using MVA VTI) is 2.3 cm². The peak transmitral gradient is 10.97 mmHg. The mean transmitral gradient is 4.68 mmHg.

Aortic Valve: Trileaflet aortic valve. Aortic cusps appear moderately calcified. Trace aortic valve regurgitation. Mild aortic valve stenosis. The peak transaortic gradient is 21.07 mmHg. The mean transaortic gradient is 14.07 mmHg. The aortic valve area by the

continuity equation (using VTI) is 2.24 cm². The aortic valve area by the continuity equation (using Vmax) is 1.94 cm². The peak velocity across the aortic valve is 2.3 m/s. The aortic valve velocity time interval is 42.66 cm². There is aortic sclerosis.

Tricuspid Valve: The tricuspid valve is not well visualized. There is mild tricuspid regurgitation. The estimated right ventricular systolic pressure is 46 mmHg. Estimated pulmonary artery systolic pressure is consistent with moderate pulmonary hypertension (45-60mmHg).

Pulmonic Valve: The pulmonic valve is not well visualized. There is mild pulmonic regurgitation.

Pericardium: Normal pericardium without evidence of pericardial effusion. There is an anterior echo free space consistent with epicardial fat pad.

Aorta: There is severe aortic root dilation. There is moderate ascending aorta dilation. The aortic root diameter 2D is 4.85 cm. The ascending aorta is 4.74 cm.

IVC: The IVC (inferior vena cava) was >2.1 cm and collapsibility >50%. The RA pressure is estimated to be 8 mmHg.

MEASUREMENTS:

2D/MM Value Range Doppler Value

LVIDd 2D 4.62 cm [4.20 - 5.80] AV Peak Vel 2.30 m/s

LVIDs 2D 3.37 cm [2.50 - 4.00] AV Peak PG 21.07 mmHg

IVSd 2D 1.64 cm [0.60 - 1.00] AV Mean PG 14.07 mmHg

LVPWd 2D 1.20 cm [0.60 - 1.00] AV VTI 42.66 cm

LV FS 2D 26.97 % [25.00 - 43.00] LVOT Peak Vel 1.22 m/s

LV Mass 2D 267.12 g LVOT Peak PG 5.98 mmHg

LV Mass Index 2D 92.43 LVOT Mean PG 4.03 mmHg

RWT 0.52 LVOT VTI 26.12 cm

EDV 2D 98.33 LVOT Diam 2.16 cm

ESV 2D 46.43 AVA VTI 2.24 cm²

EF Teich 2D 53 % AVA Vmax 1.94 cm²

LA Dimension 2D 4.99 cm [3.00 - 4.00] LVOT/AV VTI 0.61 - Dimensionless index (DVI)

LA Volume BP 116.18 ml MV E Peak Vel 1.55 m/s

LA Volume Index 40.20 MV Peak Vel 1.66 m/s

RV Base Dimen 2D 4.9 cm [2.5 - 4.2] MV Peak PG 10.97 mmHg

TAPSE 1.98 cm MV Mean PG 4.68 mmHg

RA Area 22.85 cm² [10.00 - 18.00] MV VTI 41.44 cm

IVC Diam 2.47 cm MV PHT 78.02 msec

AoR Diam 2D 4.85 cm [3.10 - 3.70] MVA PHT 2.82 cm²

ACS MM 1.62 cm Med E` Vel 0.061 m/s

Asc Ao Diam 2D 4.74 cm [2.60 - 3.40] Lat E` Vel 0.071 m/s

Average E/E` 23.48

TR Peak Vel 3.09 m/s

TR Peak PG 38.2 mmHg

RA Pressure 8.00 mmHg

RVSP 46.20

PV Peak Vel 0.81 m/s
PV Peak PG 2.63 mmHg
PV Mean PG 1.73 mmHg
PV Accel Time 102.76 msec
RVOT VTI 14.39
MVA VTI 2.31 cm

Electronically Signed By:
Orson Go, MD
2025-08-07 14:51:00 PDT

EJECTION FRACTION

%

Value
55-60

Authorizing provider: Orson Go, MD
Collection date: Jul 25, 2025 4:14 PM
Result date: Aug 07, 2025 2:56 PM
Result status: Final



Sutter Medical Center, Sacramento
 2825 Capitol Ave.
 Sacramento, CA 95816
 (916) 887-0000



TRANSTHORACIC ECHO (TTE) LIMITED

Name:	BARRY HILLS	Accession #:	MCK25005845521
MR#:	61147341	Admission Number:	1449353798
Study Date:	09/10/2025	Study Time:	04:03 PM
Date Of Birth:	04/18/1956	Age:	69 years
Height:	75 in. (190.5 cm)	Weight:	368.56 lbs. (167.18 kg)
BSA:	2.85 m2	Gender:	Male
Blood Pressure:	145 mmHg / 74 mmHg	Heart Rate:	59 bpm
Rhythm:			

Clinical Indications

Hypertrophic cardiomyopathy, Camzyos

Procedure Staff

Ultrasound Technologist: Katherine Nicoletti, RDCS
Reading Physician: Zi-Jian Xu, MD
Ordering Physician: Zi-Jian Xu, MD

Exam Details

Procedure Components: Limited 2D imaging, Limited spectral Doppler, Color Doppler
Procedure Status: Routine study
Image Quality: The study was limited due to poor acoustic windows
Technical Limitations: Echocardiographic views were limited due to body habitus, Echocardiographic views were limited by poor acoustic window availability
Facility Location: Outpatient Echo
 Camzyos 5 mg Hx: obesity, afib, HOCM

CONCLUSIONS

- Normal global systolic left ventricular function.
- LVEF range is estimated at 65 % - 70 %.
- LVOT PGmax with valsalva measures up to 77 mmHg.

FINDINGS

LEFT VENTRICLE: Normal global systolic left ventricular function. EF evaluated by visual assessment. LVEF range is estimated at 65 % - 70 %. LVOT Vmax measures up to 3.73 m/s. LVOT Vmax with valsalva measures up to 4.38 m/s. LVOT PGmax with valsalva measures up to 77 mmHg. LVOT PGmax: 56 mmHg.

Measurements**Left Ventricle**

Label	Value	Normal Value
LVOT Vmax	3.73 m/s	(0.7m/s to 1.1m/s)
LVOT PGmax	56 mmHg	
LVDd, 2D	4.2 cm	(4.2cm to 5.8cm)
LVDs, 2D	2.9 cm	(2.5cm to 4cm)
IVSd, 2D	1.6 cm	(0.6cm to 1.2cm)
LVPWd, 2D	1.1 cm	(0.6cm to 1cm)
FS, 2D	30.95 %	
LVEF, BP		(54% to 74%)
LVEF, 2D	59 %	(54% to 74%)
LV Mass, 2D ASE	212.28 g	(96g to 200g)
LVSV, BP	75 ml	
LV Mass Index, 2D ASE	74.5 g/m ²	(50g/m ² to 102g/m ²)
LVEDV Index, BP	38.6 ml/m ²	(34ml/m ² to 74ml/m ²)
LVESV Index, BP	12.3 ml/m ²	(11ml/m ² to 31ml/m ²)
LVSV Index, BP	26.3 ml/m ²	
LVOT PGmax (Valsalva)	77 mmHg	
EF lower range (%)	65 %	
EF upper range (%)	70 %	
LVOT Vmax (Valsalva)	4.38 m/s	

Electronically signed by Zi-Jian Xu, MD on 09/11/2025 at 12:58 PM

(No Signature Object)

TRANSTHORACIC ECHO (TTE) LIMITED

Collected on Sep 10, 2025 4:03 PM

If you have questions or concerns regarding your test results,
contact the clinician who ordered the test.



Results

Sutter Medical Center, Sacramento
2825 Capitol Ave.

Sacramento, CA 95816
(916) 887-0000

TRANSTHORACIC ECHO (TTE) LIMITED

Name: BARRY HILLS Accession #: MCK25005845521
MR#: 61147341 Admission Number: 1449353798
Study Date: 09/10/2025 Study Time: 04:03 PM
Date Of Birth: 04/18/1956 Age: 69 years
Height: 75 in. (190.5 cm) Weight: 368.56 lbs. (167.18 kg)
BSA: 2.85 m2 Gender: Male
Blood Pressure: 145 mmHg / 74 mmHg Heart Rate: 59 bpm
Rhythm:

Clinical Indications
Hypertrophic cardiomyopathy, Camzyos

Procedure Staff
Ultrasound Technologist: Katherine Nicoletti, RDCS
Reading Physician: Zi-Jian Xu, MD
Ordering Physician: Zi-Jian Xu, MD

Exam Details
Procedure Components: Limited 2D imaging, Limited spectral Doppler, Color Doppler
Procedure Status: Routine study
Image Quality: The study was limited due to poor acoustic windows
Technical Limitations: Echocardiographic views were limited due to body habitus,
Echocardiographic views were

limited by poor acoustic window availability

Facility Location: Outpatient Echo

Camzyos 5 mg Hx: obesity, afib, HOcm

CONCLUSIONS

- Normal global systolic left ventricular function.
- LVEF range is estimated at 65 % - 70 %.
- LVOT PGmax with valsalva measures up to 77 mmHg.

FINDINGS

LEFT VENTRICLE: Normal global systolic left ventricular function. EF evaluated by visual assessment. LVEF range is estimated at 65 % - 70 %. LVOT Vmax measures up to 3.73 m/s. LVOT Vmax with valsalva measures up to 4.38 m/s.

LVOT PGmax with valsalva measures up to 77 mmHg. LVOT PGmax: 56 mmHg.

Measurements

Left Ventricle

Label Value Normal Value

LVOT Vmax 3.73 m/s (0.7m/s to 1.1m/s)

LVOT PGmax 56 mmHg

LVDd, 2D 4.2 cm (4.2cm to 5.8cm)

LVDs, 2D 2.9 cm (2.5cm to 4cm)

IVSd, 2D 1.6 cm (0.6cm to 1.2cm)

LVPWd, 2D 1.1 cm (0.6cm to 1cm)

FS, 2D 30.95 %

LVEF, BP (54% to 74%)

LVEF, 2D 59 % (54% to 74%)

LV Mass, 2D ASE 212.28 g (96g to 200g)

LVSv, BP 75 ml

LV Mass Index, 2D 74.5 g/m² (50g/m² to 102g/m²)

ASE

LVEDV Index, BP 38.6 ml/m² (34ml/m² to 74ml/m²)

LVESV Index, BP 12.3 ml/m² (11ml/m² to 31ml/m²)

LVSv Index, BP 26.3 ml/m²

LVOT PGmax 77 mmHg

(Valsalva)

EF lower range (%) 65 %

EF upper range (%) 70 %

LVOT Vmax (Valsalva) 4.38 m/s

Electronically signed by Zi-Jian Xu, MD on 09/11/2025 at 12:58 PM

(No Signature Object)

LVEF biplane

Normal value: Normal Range (52% - 72%) to

Value

(54%

 Scan 1

Authorizing provider: Zi Xu, MD

Reading physician: Zi Xu, MD

Study date: Sep 10, 2025 4:00 PM

Collection date: Sep 10, 2025 4:03 PM

Result date: Sep 11, 2025 12:58 PM

Result status: Final



Sutter Medical Center, Sacramento
 2825 Capitol Ave.
 Sacramento, CA 95816
 (916) 887-0000



TRANSTHORACIC ECHO (TTE) LIMITED

Name:	BARRY HILLS	Accession #:	MCK25005845568
MR#:	61147341	Admission Number:	1449354369
Study Date:	10/08/2025	Study Time:	02:51 PM
Date Of Birth:	04/18/1956	Age:	69 years
Height:	75 in. (190.5 cm)	Weight:	361 lbs. (163.75 kg)
BSA:	2.82 m2	Gender:	Male
Blood Pressure:	121 mmHg / 70 mmHg	Heart Rate:	63 bpm
Rhythm:			

Clinical Indications

HCM

Procedure Staff

Ultrasound Technologist: Kontear Peng, RDCS
Reading Physician: Zi-Jian Xu, MD
Ordering Physician: Zi-Jian Xu, MD
Reading Group: SMCS - Heart Failure

Exam Details

Procedure Components: Limited 2D imaging, Limited spectral Doppler, Color Doppler
Procedure Status: Routine study
Image Quality: Technically Difficult
Technical Limitations: Echocardiographic views were limited due to body habitus
Facility Location: Outpatient Echo
 HX: Camzygos 5mg, obesity

CONCLUSIONS

- Systolic left ventricular function is hyperdynamic .
- LVEF estimated visually at 75 %.
- LVOT PGmax with valsalva measures 94 mmHg.

Prior Echocardiography Studies:

There is a prior study dated 09/10/2025.

FINDINGS

LEFT VENTRICLE: Systolic left ventricular function is hyperdynamic . EF evaluated by visual assessment. LVEF

estimated visually at 75 %. LVOT Vmax measures 4.30 m/s. LVOT Vmax with valsalva measures 4.90 m/s. LVOT PGmax with valsalva measures 94 mmHg. LVOT PGmax: 74 mmHg.

Measurements

Left Ventricle

Label	Value	Normal Value
LVOT Vmax	4.30 m/s	(0.7m/s to 1.1m/s)
LVOT PGmax	74 mmHg	
LVEF visual	75 %	(55% to 75%)
LVDD, 2D	5.4 cm	(4.2cm to 5.8cm)
LVDs, 2D	3.5 cm	(2.5cm to 4cm)
IVSd, 2D	2 cm	(0.6cm to 1.2cm)
LVPWd, 2D	1.5 cm	(0.6cm to 1cm)
FS, 2D	35.19 %	
LVEF, 2D	64 %	(54% to 74%)
LV Mass, 2D ASE	456.12 g	(96g to 200g)
LVSV, BP	78 ml	
LV Mass Index, 2D ASE	161.7 g/m ²	(50g/m ² to 102g/m ²)
LVEDV Index, BP	41.5 ml/m ²	(34ml/m ² to 74ml/m ²)
LVESV Index, BP	13.8 ml/m ²	(11ml/m ² to 31ml/m ²)
LVSV Index, BP	27.7 ml/m ²	
LVOT PGmax (Valsalva)	94 mmHg	
LVOT Vmax (Valsalva)	4.90 m/s	

Mitral Valve

Label	Value	Normal Value
MR Vmax	2.64 m/s	
MR Pmax	28 mmHg	

Electronically signed by Zi-Jian Xu, MD on 10/08/2025 at 06:27 PM

(No Signature Object)



Sutter Medical Center, Sacramento
 2825 Capitol Ave.
 Sacramento, CA 95816
 (916) 887-0000



TRANSTHORACIC ECHO (TTE) LIMITED

Name:	BARRY HILLS	Accession #:	MCK26000064304
MR#:	61147341	Admission Number:	1496788024
Study Date:	01/06/2026	Study Time:	03:49 PM
Date Of Birth:	04/18/1956	Age:	69 years
Height:	75 in. (190.5 cm)	Weight:	360 lbs. (163.29 kg)
BSA:	2.82 m2	Gender:	Male
Blood Pressure:	128 mmHg / 67 mmHg	Heart Rate:	64 bpm
Rhythm:			

Clinical Indications

Hypertrophic cardiomyopathy

Procedure Staff

Ultrasound Technologist: Mikhail Pavlov, RDCS
Reading Physician: Zi-Jian Xu, MD
Ordering Physician: Zi-Jian Xu, MD
Reading Group: SMCS - Heart Failure

Exam Details

Procedure Components: Limited 2D imaging, Limited spectral Doppler, Color Doppler
Procedure Status: Routine study
Image Quality: Adequate
Consent: Risks, alternatives of procedure explained to patient, informed consent obtained
Probe Insertion: Attending cardiologist
Facility Location: Outpatient Echo
 Hx: HOCM, HTN, HLD, IHSS, aFIB, aortic aneurysm, bradycardia, ablation of aFib, hypertensive disorder, and ventricular arrhythmia. 10mg Camzyos

Acute complication: No complications

CONCLUSIONS

- Systolic left ventricular function is hyperdynamic .
- LVEF range is estimated at 70 % - 75 %.
- LVOT PGmax with valsalva measures 45 mmHg.

Prior Echocardiography Studies:

There is a prior study dated 11/18/2025.

Echo:

There has been no significant interval change.

FINDINGS

LEFT VENTRICLE: Systolic left ventricular function is hyperdynamic . EF evaluated by visual assessment. LVEF range is estimated at 70 % - 75 %. Left ventricle wall thickness is severely increased. LVOT Vmax measures 2.42 m/s. LVOT Vmax with valsalva measures 3.35 m/s. LVOT PGmax with valsalva measures 45 mmHg. LVOT PGmax: 23 mmHg.

Measurements

Left Ventricle			Mitral Valve		
Label	Value	Normal Value	Label	Value	Normal Value
LVOT Vmax	2.42 m/s	(0.7m/s to 1.1m/s)	MR Vmax	4.41 m/s	
LVOTd	2.1 cm	(1.9cm to 2.1cm)	MR Pmax	78 mmHg	
LVOT PGmax	23 mmHg				
LVDD, 2D	4.2 cm	(4.2cm to 5.8cm)			
LVDS, 2D	2.8 cm	(2.5cm to 4cm)			
IVSd, 2D	1.9 cm	(0.6cm to 1.2cm)			
LVPWd, 2D	1.8 cm	(0.6cm to 1cm)			
FS, 2D	33.33 %				
LVEF, 2D	62 %	(54% to 74%)			
LV Mass, 2D ASE	349.17 g	(96g to 200g)			
LVSV, BP	84 ml				
LV Mass Index, 2D ASE	123.8 g/m ²	(50g/m ² to 102g/m ²)			
LVEDV Index, BP	46.1 ml/m ²	(34ml/m ² to 74ml/m ²)			
LVESV Index, BP	16.3 ml/m ²	(11ml/m ² to 31ml/m ²)			
LVSV Index, BP	29.8 ml/m ²				
LVOT PGmax (Valsalva)	45 mmHg				
LVOT Area	3.5 cm ²				
EF lower range (%)	70 %				
EF upper range (%)	75 %				
LVOT Vmax (Valsalva)	3.35 m/s				

Electronically signed by Zi-Jian Xu, MD on 01/07/2026 at 03:19 PM

(No Signature Object)



Sutter Medical Center, Sacramento
2825 Capitol Ave.
Sacramento, CA 95816
(916) 887-0000



TRANSTHORACIC ECHO (TTE) LIMITED

Name:	BARRY HILLS	Accession #:	MCK26000552114
MR#:	61147341	Admission Number:	1511621828
Study Date:	01/30/2026	Study Time:	02:53 PM
Date Of Birth:	04/18/1956	Age:	69 years
Height:	75 in. (190.5 cm)	Weight:	370 lbs. (167.83 kg)
BSA:	2.85 m ²	Gender:	Male
Blood Pressure:	127 mmHg / 79 mmHg	Heart Rate:	60 bpm
Rhythm:			

Clinical Indications

Hypertrophic cardiomyopathy

Procedure Staff

Ultrasound Technologist: Cori Brunet, RDCS
Reading Physician: Zi-Jian Xu, MD
Ordering Physician: Zi-Jian Xu, MD
Reading Group: SMCS - Heart Failure

Exam Details

Procedure Components: Limited 2D imaging, Limited spectral Doppler, Color Doppler
Procedure Status: Routine study
Image Quality: Adequate
Facility Location: Inpatient Bedside Echo
History of HOCM, AFib s/p ablation, HTN, OSA, HLD.
Atrial flutter is present during today's Echo study

CONCLUSIONS

- Systolic left ventricular function is hyperdynamic .
- LVEF estimated visually at 70 %.
- LVOT PGmax with valsalva measures 38 mmHg (average of 3 beats).

Prior Echocardiography Studies:

There is a prior study dated 01/06/2026. LVOT PG with valsalva has decreased; however, previously reported valvule represented the maximal PG from a single beat, instead of average of 3 beats reported here on current study..

FINDINGS

LEFT VENTRICLE: Systolic left ventricular function is hyperdynamic . EF evaluated by visual assessment. LVEF

estimated visually at 70 %. Left ventricle wall thickness is severely increased. LVOT PGmax with valsalva measures 38 mmHg (average of 3 beats).

Measurements

Left Ventricle

Label	Value	Normal Value
LVEF visual	70 %	(55% to 75%)
LVDd, 2D	3.9 cm	(4.2cm to 5.8cm)
LVDs, 2D	2.8 cm	(2.5cm to 4cm)
IVSd, 2D	1.8 cm	(0.6cm to 1.2cm)
LVPWd, 2D	1.8 cm	(0.6cm to 1cm)
FS, 2D	28.21 %	
LVEF, 2D	56 %	(54% to 74%)
LV Mass, 2D ASE	302.25 g	(96g to 200g)
LV Mass Index, 2D ASE	106.1 g/m ²	(50g/m ² to 102g/m ²)
LVOT PGmax (Valsalva)	38 mmHg	
LVOT Vmax (Valsalva)	3.10 m/s	


Electronically signed by Zi-Jian Xu, MD on 02/01/2026 at 02:12 PM

(No Signature Object)

Name: Barry Laurence Hills | DOB: 4/18/1956 | Legal Name: Barry Laurence Hills

TRANSTHORACIC ECHO (TTE) LIMITED

Collected on Mar 26, 2026 1:23 PM

If you have questions or concerns regarding your test results, contact the clinician who ordered the test. 

Results

Sutter Medical Center, Sacramento
2825 Capitol Ave.

Sacramento, CA 95816
(916) 887-0000

TRANSTHORACIC ECHO (TTE) LIMITED

Name: BARRY HILLS Accession #: MCK26000552246
MR#: 61147341 Admission Number: 1511628601
Study Date: 03/26/2026 Study Time: 01:23 PM
Date Of Birth: 04/18/1956 Age: 69 years
Height: 75 in. (190.5 cm) Weight: 364 lbs. (165.11 kg)
BSA: 2.83 m2 Gender: Male
Blood Pressure: 128 mmHg / 51 mmHg Heart Rate:
Rhythm:

Clinical Indications
HCM, 15mg camzyos

Procedure Staff
Ultrasound Technologist: Rian Donaire, RDCS
Reading Physician: Zi-Jian Xu, MD
Ordering Physician: Zi-Jian Xu, MD
Reading Group: SMCS - Heart Failure

Exam Details
Procedure Components: Limited 2D imaging
Procedure Status: Routine study
Image Quality: Adequate
Facility Location: Outpatient Echo
hx of htn

CONCLUSIONS

- Normal global systolic left ventricular function.
 - LVEF estimated visually at 65 %.
 - LVOT PGmax with valsalva measures 10 mmHg.
-

Prior Echocardiography Studies:

There is a prior study dated 01/30/2026. LVOT PGmax with valsalva has decreased (38 mmHg previously).

FINDINGS

LEFT VENTRICLE: Normal global systolic left ventricular function. EF evaluated by visual assessment. LVEF estimated visually at 65 %. Left ventricle wall thickness is severely increased. There are no regional wall motion abnormalities.

LVOT Vmax measures 1.09 m/s. LVOT Vmax with valsalva measures 1.59 m/s. LVOT PGmax with valsalva measures 10 mmHg. LVOT PGmax: 5 mmHg.

AORTIC VALVE: AV Vmax, Caliper: 1.35 m/s. AV PGmean: 4 mmHg.

Measurements

Left Ventricle Aortic Valve

Label Value Normal Value Label Value Normal Value

LVOT Vmax 1.09 m/s (0.7m/s to 1.1m/s) AV Vmean 1.00 m/s

LVOT PGmax 5 mmHg AV VTI 30.00 cm

LVEF visual 65 % (55% to 75%) AV PGmax 7 mmHg

LVDd, 2D 4.1 cm (4.2cm to 5.8cm) AV PGmean 4 mmHg

LVDs, 2D 3.1 cm (2.5cm to 4cm) AV Vmax, Caliper 1.35 m/s (1m/s to 1.7m/s)

IVSd, 2D 2.3 cm (0.6cm to 1.2cm) DI Vmax 0.81

LVPWd, 2D 2.1 cm (0.6cm to 1cm)

FS, 2D 24.39 %

LVEF, 2D 50 % (54% to 74%)

LV Mass, 2D ASE 454.21 g (96g to 200g)

LV Mass Index, 2D 160.5 g/m² (50g/m² to 102g/m²)

ASE

LVOT PGmax 10 mmHg

(Valsalva)

LVOT Vmax (Valsalva) 1.59 m/s

Electronically signed by Zi-Jian Xu, MD on 03/27/2026 at 03:45 PM

(No Signature Object)

 Scan 1

Authorizing provider: Zi Xu, MD

Reading physician: Zi Xu, MD

Study date: Mar 26, 2026 1:23 PM

Collection date: Mar 26, 2026 1:23 PM

Result date: Mar 27, 2026 3:45 PM

Result status: Final

MyChart® licensed from Epic Systems Corporation© 1999 - 2026